

**DATE PRESENTING CLINICAL SIGNS**

6/1/2022

PATIENT

Mr. Darcy Novak

P has an approximately one-month history of recurrent mixed bowel diarrhea. Has not resolved with metronidazole, probiotics. History of sensitive stomach/intermittent GI upset. History of calcium oxalate stones (on urinary diet), previous hemilaminectomy, FHO, and anal Sacculectomy.

SPECIES

Canine

Current Medications: Gabapentin 25mg Q12-24hours, Famotidine 5mg, Loratidine 10mg, Quellin: Has been getting 1/2 tab am, 1/4 tab pm

Virbac Movoflex Joint support, Vetquinol Flexadin Plus joint, Potassium citrate K Plus BID, Ketofen ophthalmic for seasonal allergies, Cytopoint

Lab Results: Previous BW all WNL, Spec CPL WNL, Texas GI Panel – Pending.

BREED

Dachshund Mix

Date of Previous IntraPet Ultrasound: No previous.

Sedation: Not required to complete full diagnostic ultrasound.

Stat Report: Not requested.

Imaging Performed By: Stephanie Pearce RDCS, RVT.

SEX

Neutered Male

ULTRASONOGRAPHIC EXAMINATION OF THE ABDOMEN**AGE**

5/20/2010

Urinary System**WEIGHT**

21.5 lbs

The urinary bladder, trigone, and pelvic urethra are normal in thickness and the mucosal surface is smooth. The bladder lumen is moderately distended with mostly anechoic urine. No masses, inflammatory changes or calculi are observed. Ureteral papillae and visualized portion of the proximal urethra, visible to a depth of 2 cm, are normal.

The prostate is normal in size (0.80 cm in width) and shape. Parenchyma is homogenous. The prostatic urethra appears normal without evidence of dilation or obstruction.

INTERPRETED BY

Andrea Nicastro, DMV,
Diplomate DACVIM
(Small Animal
Internal Medicine)

The left kidney is normal in size (4.22 cm in length) with a normal shape, smooth peripheral margins, and normal internal architecture. There is minimal loss of corticomedullary distinction. Several hyperechoic shadowing diverticular foci are observed. A few, nonobstructive nephroliths are visualized. There is no evidence of pyelectasia, infarcts or hydroureter. Renal vasculature is normal.

HOSPITAL NAME

Paradise Animal
Hospital

The right kidney is normal in size (4.48 cm in length) with a normal shape, smooth peripheral margins, and normal internal architecture. There is minimal loss of corticomedullary distinction. Several hyperechoic shadowing diverticular foci are observed. There is no evidence of pyelectasia, infarcts or hydronephrosis. Renal vasculature is normal.

REFERRING VET

Dr. Pound

Adrenal Glands**INVOICE**

11002

The left adrenal gland is normal size (0.45 cm at cranial pole) (0.51 cm at caudal pole) (1.64 cm in length); normal shape; homogenous parenchyma. The glandular echogenicity and detail are unremarkable. Capsule, cortex, and medullary definition are normal. The phrenicoabdominal vein and surrounding vasculature are normal.

The right adrenal gland is normal size (0.42 cm at cranial pole) (0.43 cm at caudal pole) (1.95 cm in length); normal shape; homogenous parenchyma. The glandular echogenicity and detail are unremarkable. Capsule, cortex, and medullary definition are normal. The phrenicoabdominal vein and surrounding vasculature are normal.

Spleen

The spleen is normal in size (1.25 cm in width at the level of the hilus) with a normal capsular contour. There is appropriate echogenicity and echotexture. A few, small, ill-defined myelolipomas are observed in the region of the hilus. Splenic vasculature is normal.

Liver

The liver is subjectively normal in size with normal contours and structure. There is appropriate echogenicity and echotexture. No overt structural evidence of inflammatory, infiltrative, or regenerative pathology is evident. Vascular and biliary tracts are of normal volume with no evidence of congestion. No pathological hepatic lymphadenopathy observed.

The gall bladder lumen is moderately distended. The wall is thin and smooth. A moderate amount of aggregated, echogenic to mineralized, mostly gravity dependent, debris/sludge is observed within the lumen. The cystic and common bile ducts are normal/not seen.

Gastrointestinal

The stomach and intestine are free of stasis and exhibit normal peristaltic activity. The gastric lumen is not distended. The gastric wall and pylorus are normal in thickness with a normal layering pattern. The pyloric outflow tract is patent. The small intestinal lumen is not dilated. The small intestinal wall thickness is normal with a normal layering pattern and appropriate mural detail. Discreet masses are not identified. The ileocecolic junction and colonic wall are normal. The colonic length is subjectively shorter than normal. There is no evidence of an obstructive pattern.

Pancreas

The region of the pancreas is isoechoic relative to surrounding omental fat. No obvious parenchymal abnormalities are observed. There is no evidence of regional inflammation or effusion.

Free Abdomen

The peritoneal cavity is normal. There is no evidence of inflammation or effusion. The abdominal lymph nodes are normal/not visible.

ULTRASONOGRAPHIC FINDINGS

Primary Findings

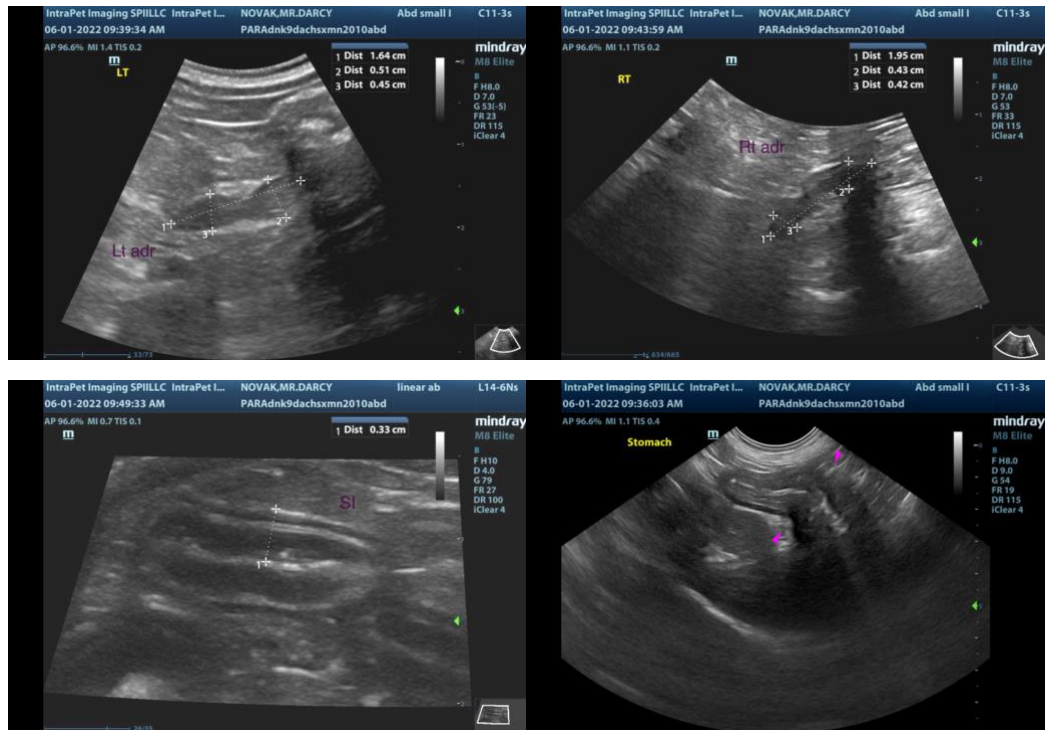
- Possible short colonic length

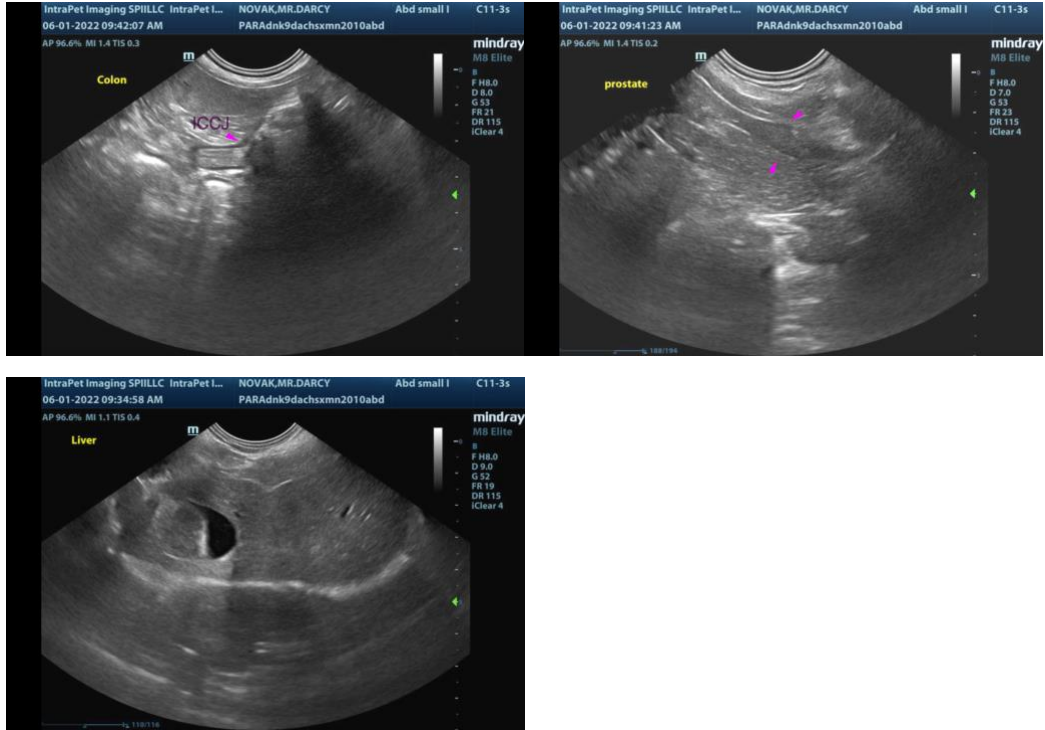
Secondary Findings

- Bilateral, nonobstructive nephrolcalcinosis
- Gall bladder sludge, non-mucocele

INTERPRETATION OF THE FINDINGS & FURTHER RECOMMENDATIONS

- Fecal evaluation for ova and Giardia, if not already performed
- Prophylactic deworming with Fenbendazole at 50 mg/kg once a day for 5 days is recommended. Repeat above protocol in 3 weeks.
- A resting cortisol level to screen for hypoadrenocorticism. If resting cortisol level is < 2.0 mcg/dL, an ACTH stimulation test is recommended.
- A 6-week limited antigen diet trial to assess for food allergies
- Depending on the results of the above diagnostics as well as the GI panel, GI biopsy, endoscopic or surgical, may be necessary to get a definitive diagnosis. If pursued, thoracic radiographs should be performed prior to anesthesia.





The information and recommendations provided are based on the images presented by the referring veterinarian/sonographer. No evaluation can be communicated regarding pathology that was not visible in the image/video clips provided.

Thank you for this referral. If the clinical or image interpretation does not parallel your findings or if I can be of any further assistance, please contact me.

Andrea Nicastro, DVM, Diplomate DACVIM (Small Animal Internal Medicine)
info@SonoPath.com